UNIVERSITÉ DE LORRAINE

ESSR

ESSR 2016
MUSCULOSKELETAL RADIOLOGY
JUNE 9–11, ZURICH/SWITZERLAND

Posterior Radioscaphoid Angle as a Predictor of Wrist Degenerative Joint Disease in Patients With Scapholunate Ligament Tears

J. De Verbizier, P. Teixeira, S. Aptel, F. Dap, G. Dautel, A. Blum

CENTRE CHIRURGICAL ÉMILE GALLÉ
TRAUMATOLOGIE • ORTHOPEDIE • CHIRURGIE DE LA MAIN

CHU NANCY
www.chu-nancy.fr

- Sapholunate ligament tears: most common and the most serious type of wrist ligament injury[1]
- SLAC : palliative treatment
- Dorsal scaphoid displacement associated with the development of SLAC wrist[2,3]

SLAC : Scapho Lunate Acute Collapse

1- Watson HK, Weinzweig J, Zeppieri J. The natural progression of scaphoid instability. Hand Clin. 1997
2- Pappou IP, Basel J, Deal DN. Scapholunate ligament injuries: a review of current concepts. HAND. 2013
3- Kitay A, Wolfe SW. Scapholunate Instability: Current Concepts in Diagnosis and Management. J Hand Surg. 2012

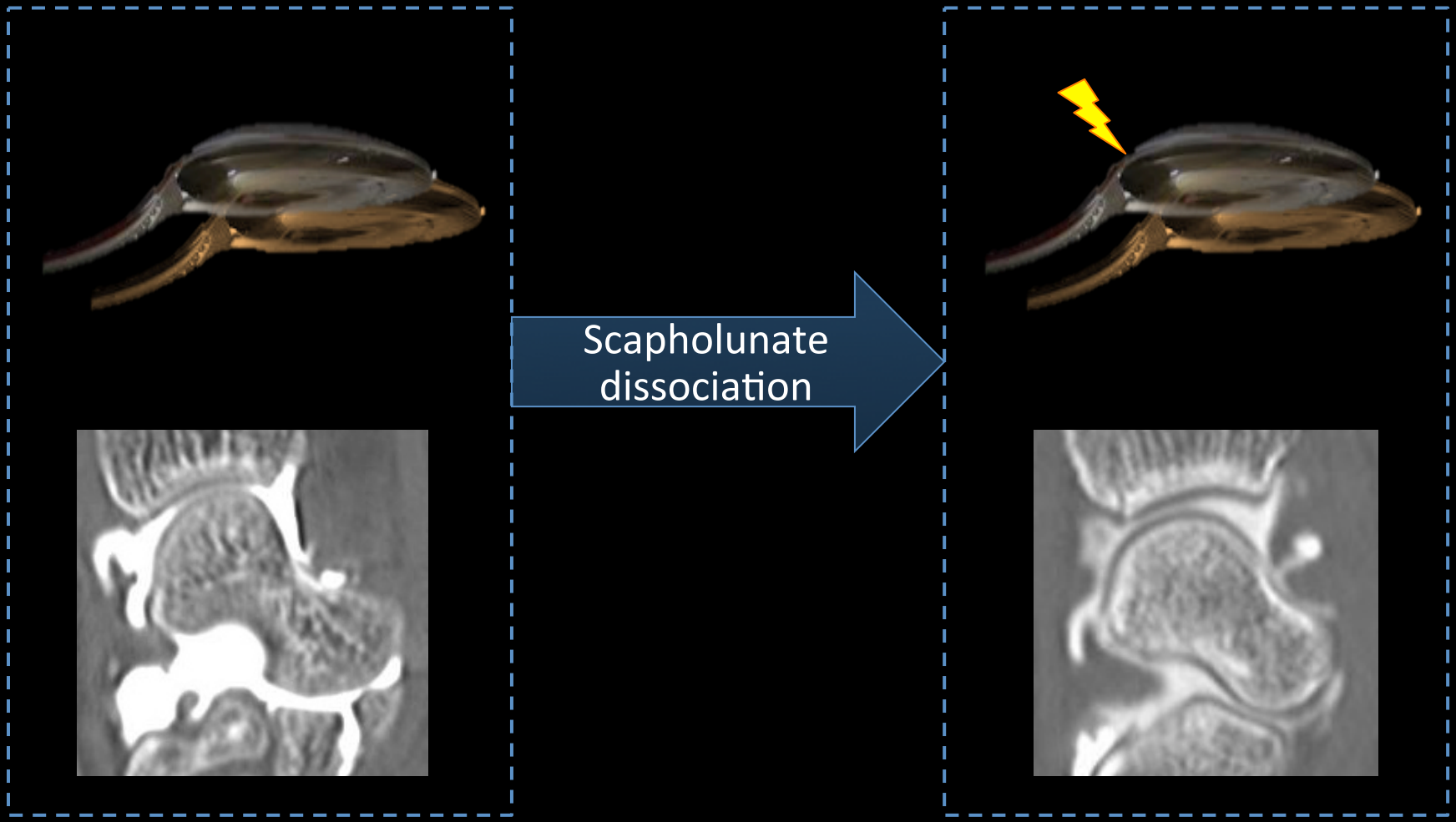

4- Watson HK, Brenner LH Degenerative disorders of the wrist. J Hand Surg 1985

- Difficulties to evaluate the dorsal displacement of scaphoid on conventional radiographs: Bone superimposition[5]
- Objective diagnostic criteria on CT[6] ?
- Posterior radioscaphoid angle (PRSA):
  - Angle formed between the radial articular surface plan and the posterior-most point of the scaphoid
- Objective: determine whether the PRSA is associated with degenerative joint disease in patients with scapholunate ligament tears

5- *Garcia-Elias M et al. Three-ligament tenodesis for the treatment of SLD: indications and surgical technique. J Hand Surg Am. 2006*
6- *Strauch RJ. SLAC and SNAC arthritis--update on evaluation and treatment. J Hand Surg Am. 2012*

Patients

- Retrospective study between 2009 and 2013
- 600 patients underwent conventional radiographs and CT arthrographies

150 patients randomised

38 exclusions:

previous wrist surgery

known inflammatory joint disease of the wrist

other types of carpal instability

112 patients

Control Group:

normal SLL or isolated tear of the membranous component

Study Group:

Tears of the dorsal or volar components of the SLL

Imaging Protocol

- Radiographs:
  - at least three views
  - PA, lateral, and posteroanterior with a clenched fist
- CT arthrography:
  - Neutral position
  - Reconstructed in all orthogonal planes
  - Bone and soft-tissue kernels

Readers

- Two radiologists with 2 and 6 years of clinical experience
- Independent analysis

CT arthrography

- Posterior most point of the scaphoid
- Posterior and anterior rims of radius

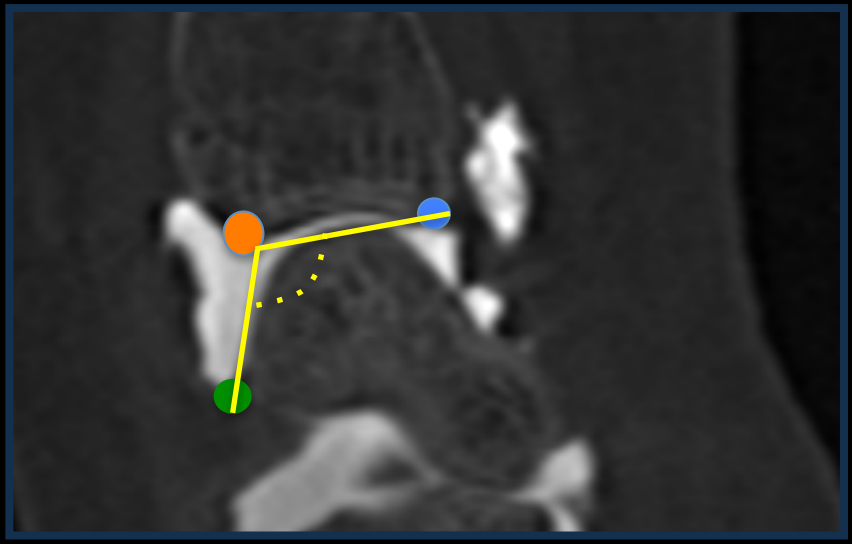

Measures

Conventional radiographs

- Scapholunate angle
- Radiolunate angle

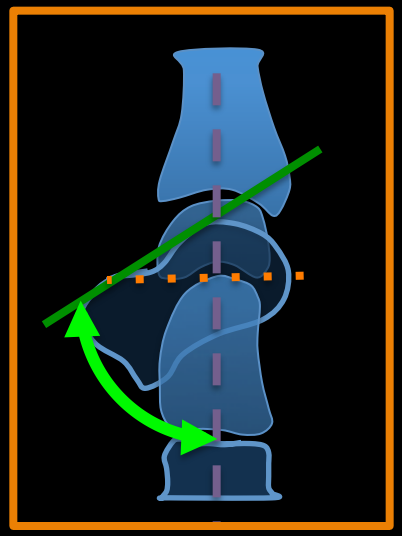

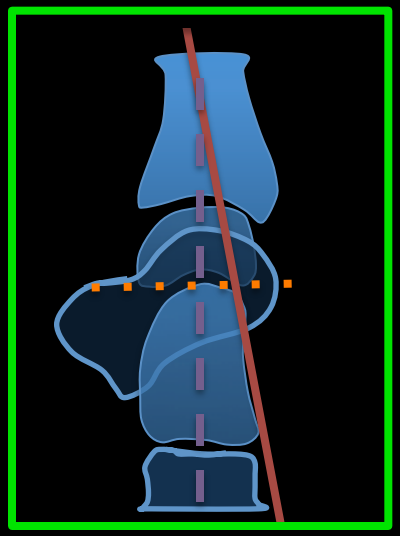

- Severity of SLAC[7,8]

7- Kitay A et al. Scapholunate instability: current concepts in diagnosis and management. J Hand Surg Am. 2012
8- Gilula LA, et al ; IWI Terminology Committee. Wrist terminology as defined by the IWIW. J Bone Joint Surg Am 2002

- 68 male et 44 female
- Mean age : 41.3 (15 à 68 years old)

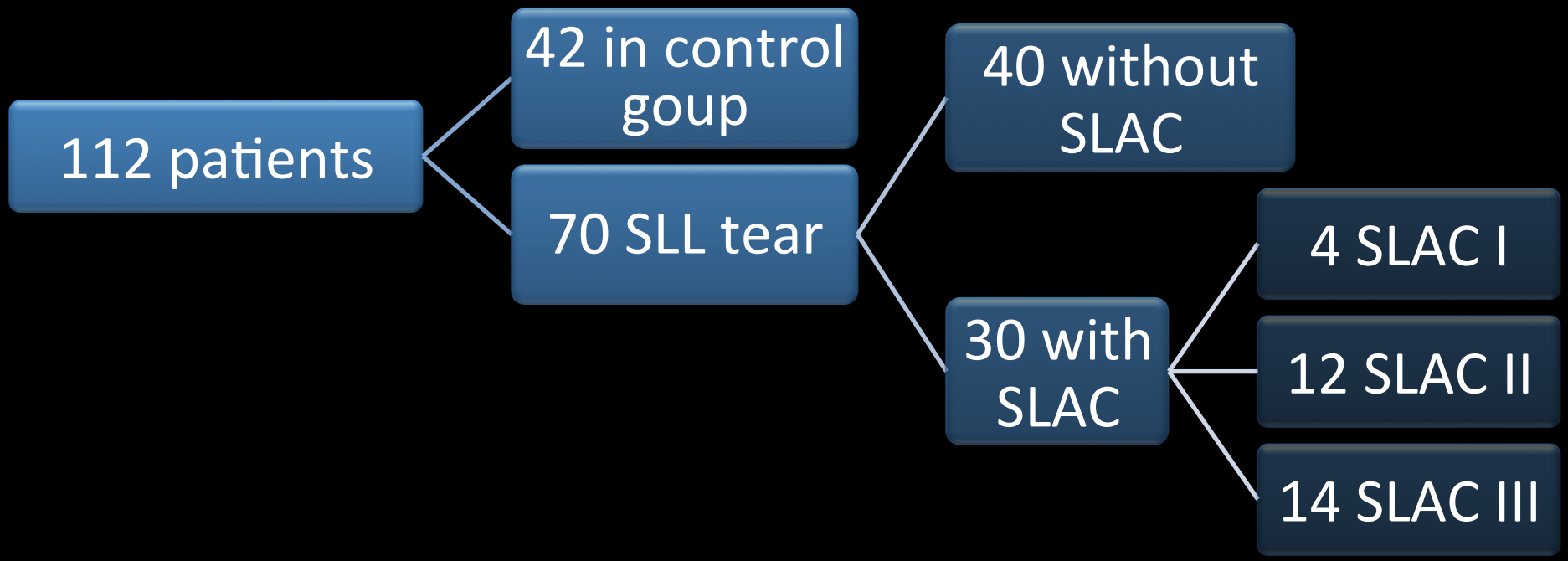

Angle	Control group	SLL tears without SLAC	SLL tears with SLAC
Scapholunate angle	53 ±11°	59 ±15°	76 ±15°
Radiolunate angle	10 ±7°	15 ± 10°	19 ± 10°
PRSA	98 ± 8°	105 ± 8°	122 ± 9°

- Intraobserver agreement was almost perfect (ICC 0,82 et 0,92)
- PRSA larger in patients with SLL rupture ($p < 0.0001$)
- No correlation between PRSA and SLAC wrist severity
- 114° was selected as the cutoff for optimal performance for the differentiation of patients with and without SLAC wrist

F 22 years old
SLL tears
Without SLAC
PRSA= 97°

F 22 years old
SLL tears
Without SLAC
PRSA= 97°

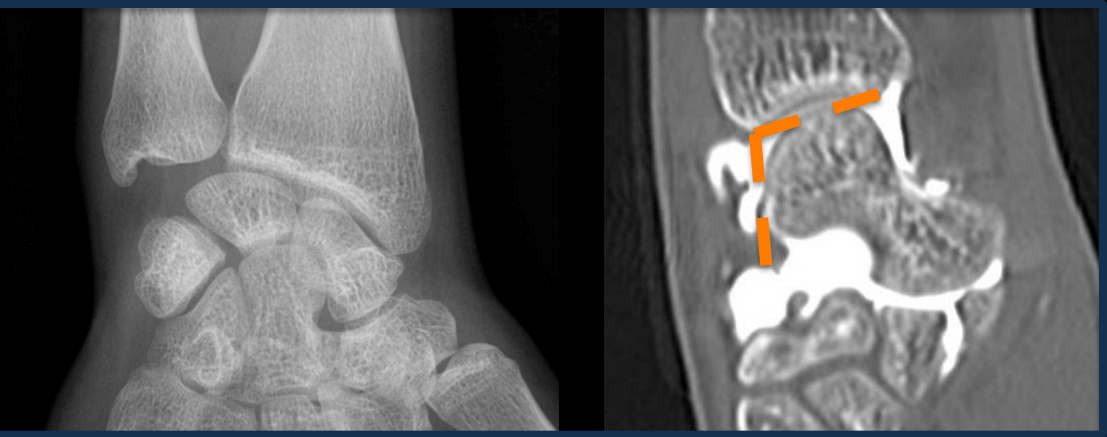

M 40 years old
LSL years
SLAC 1
PRSA = 127°

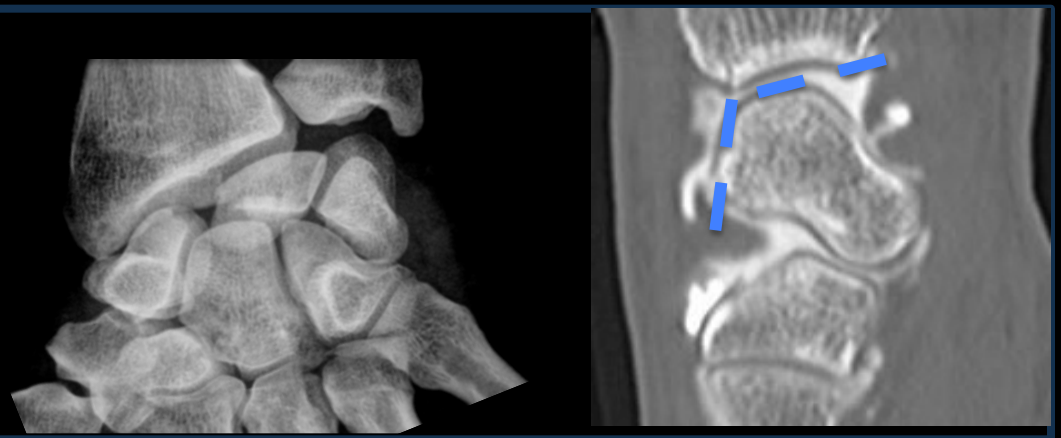

M 45 years old
Chronic wrist pain

Radiographs: no SLAC

Arthro scanner: SLL tears

1 : PRSA: 126°
2 : Early degenerative changes at radial articular surface (arrow) and at lunocapitate joint line, characterized by chondral wearing and subchondral bone irregularity (arrowheads).

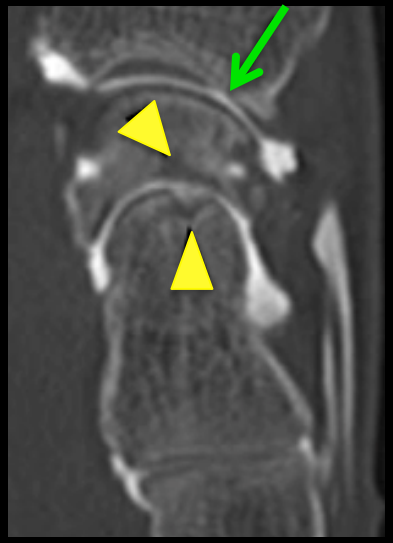

- Four PRSA> 114° without SLAC on radiograph:
  - Two of these patients: equivocal chondral damage visible on CT arthrography
  - Two other patients: young patients (18 and 22 years old):
    - Significant anomalies of carpal function
- Early surgical treatment

- Study of the posterior displacement of the scaphoid is important because it is a prognostic factor in the development of SLAC
- PRSA:
  - Quantitative tool for the evaluation of posterior displacement of the scaphoid in cases of SLL tear
  - Abnormal PRSA values : biomechanical changes with potential implications for patient management